

IMAGES

Reconstruction of the Alar-Facial Groove Using a Nasolabial Flap and Medial Directional Force with a ‘Tissue-Adding’ Effect

Chi An Lee, Jin Woo Kim

Department of Plastic and Reconstructive Surgery, Busan Baik Hospital, Inje University School of Medicine, Busan, Korea

Correspondence: Jin Woo Kim
 Department of Plastic and Reconstructive Surgery, Busan Baik Hospital, Inje University School of Medicine, 75 Bokji-ro, Busanjin-gu, Busan 47392, Korea
 Tel: +82-51-890-6136, Fax: +82-51-894-7976
 E-mail: jinooda@hanmail.net

No potential conflict of interest relevant to this article was reported.

Received: 2 Feb 2017 • Revised: 28 Apr 2017 • Accepted: 7 Jun 2017
 pISSN: 2234-6163 • eISSN: 2234-6171
<https://doi.org/10.5999/aps.2017.44.5.469>
 Arch Plast Surg 2017;44:469-470



Copyright © 2017 The Korean Society of Plastic and Reconstructive Surgeons
 This is an Open Access article distributed under the terms of the Creative Commons Attribution Non-Commercial License (<http://creativecommons.org/licenses/by-nc/4.0/>) which permits unrestricted non-commercial use, distribution, and reproduction in any medium, provided the original work is properly cited.

Reconstructing the nose, especially the alar-facial groove, is difficult because of its 3-dimensional structural characteristics. We report the case of a 33-year-old man with a history of crush injury to the nose 15 years previously. We performed reconstruction because of scar contracture formation in the left alar-facial groove (Fig. 1).

This study was reviewed and approved by the Ethics Review Board of the Inje University Health Center.

A V-Y advancement flap was designed by setting the nasolabial fold as the superior margin and the

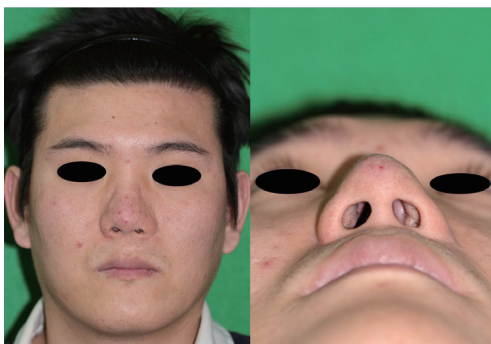

Fig. 1. Preoperative view showing the vague alar-facial groove resulting from a crush injury.

elevated alar-facial groove as the medial margin. A cutaneous perforator flap was then elevated [1]. The scar tissue in the alar-facial groove, including the skin and subcutaneous layer, was minimally excised, by 1.0 × 0.2 cm (Fig. 2).

The septum was peeled back to expose the anterior nasal spine, and the bottom surface of the alar side was fixed to a firm area near the anterior nasal spine. This can be done via open rhinoplasty or a minimal incision in the mucosa inside the nostril (Fig. 3).

The alar-side surface of the area from which the scar tissue was excised and the medial area of the nasolabial V-Y flap were sutured together. In this manner, a stronger and more prominent secondary alar-facial groove was constructed (Fig. 4).

The definitive treatment for patients needing alar-facial groove reconstruction has not been established. The skirt flap is not optimal for a prominent alar-facial groove [2], nor is the feather-edge rolled-in flap optimal for resolving the tension around the groove [3]. We used a nasolabial flap and ‘tissue-adding’ to

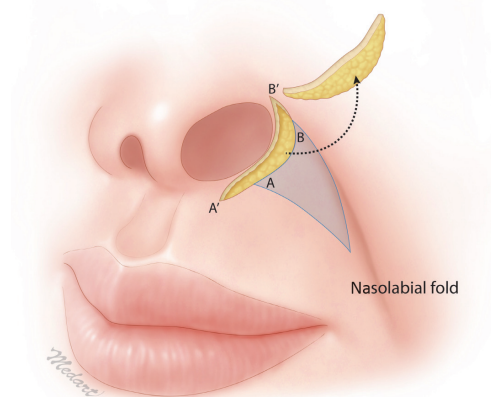


Fig. 2. Illustration of the surgical technique. Scar tissue on the alar-facial groove was resected with a minimal incision and elevated in the nasolabial fold direction with a V-Y flap design. Point A moved to A', and point B moved to B' by the V-Y advancement flap.

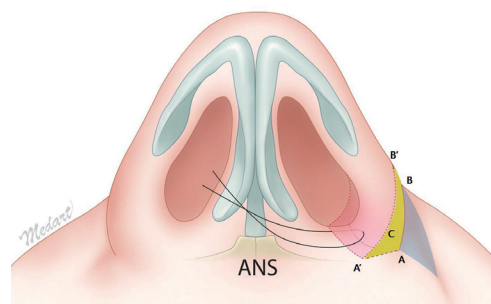


Fig. 3. Fixation of the alar base, close to the hard area of the anterior nasal spine, where it forms a reentrant alar-facial groove. The location of fixation should be decided based on the symmetry of both sides of the nasal cavity. If only reconstruction of the alar-facial groove is planned, a minimal incision can be made in the mucosa inside the nostril. The yellow (C) area corresponds to excised scar tissue. ANS, anterior nasal spine.

Images

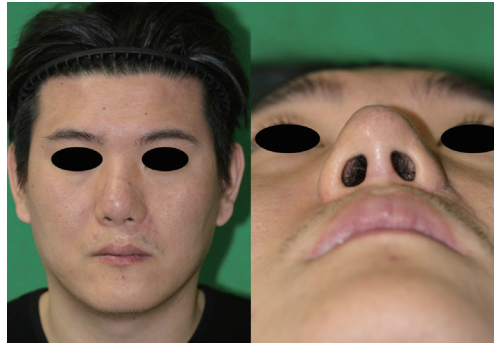

Fig. 4.

Postoperative view flap 5 months after surgery showing the formation of the reentrant area on the initially vague alar-facial groove and minimal scarring caused by the V-Y advancement.

reconstruct the alar-facial groove. This technique reduces tension and yields more prominent results by providing a force in the medial direction.

Patient Consent

The patient provided written informed consent for the publication and the use of their images.

References

1. Han D, Mangoba DS, Lee D, et al. Reconstruction of nasal alar defects in asian patients. *Arch Facial Plast Surg* 2012;14:312-7.
2. Ueda K, Shigemura Y, Hara M, et al. Skirt flap for nasal alar reconstruction. *Plast Reconstr Surg Glob Open* 2014;2:e157.
3. Park JL, Oh CH, Hwang K, et al. Correction of an alar web with a feather-edge rolled-in flap. *J Craniofac Surg* 2014;25:2192-5.

Received: 21 Feb 2017 • Revised: 11 Jun 2017 • Accepted: 22 Jun 2017
 pISSN: 2234-6163 • eISSN: 2234-6171
<https://doi.org/10.5999/aps.2017.44.5.470>
Arch Plast Surg 2017;44:470-471



Copyright © 2017 The Korean Society of Plastic and Reconstructive Surgeons
 This is an Open Access article distributed under the terms of the Creative Commons Attribution Non-Commercial License (<http://creativecommons.org/licenses/by-nc/4.0/>) which permits unrestricted non-commercial use, distribution, and reproduction in any medium, provided the original work is properly cited.

We hereby report a case of a 41-year-old woman with a history of liposuction of the right hip 6 months previously who presented to her dermatologist with bilateral recurring erythematous skin nodules. On palpation, 1 cm tender nodules were identified in the bilateral hip region in close approximation to the liposuction scars and a shave biopsy was performed from the lesions on the right side. The clinical differential diagnosis included panniculitis, tumid lupus erythematosus, and infection. A biopsy was performed and the histopathologic examination revealed an interstitial palisading granulomatous dermatitis with dermal mucin deposition confirmed by colloidal iron stain (Figs. 1–3). We examined multiple H&E sections, and there was no evidence of polarizable or non-polarizable foreign material. Special stains (Gomori Methenamine silver stain [GMS], Periodic acid-Schiff [PAS], and Acid-fast bacilli stain [AFB]) were negative for fungus and mycobacteria and culture studies performed also were negative.

In light of the patient's history of liposuction immediately adjacent to the area of the nodules, we concluded that granulomatous dermatitis was induced by the liposuction procedure. There was no known history of any injectable material used in our case. The

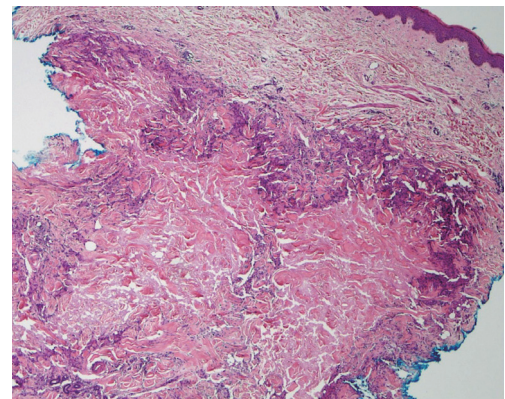


Fig. 1.

Interstitial granulomas (H&E, ×40). Section of skin showing dermal palisading granulomatous inflammation with central area of interstitial mucin deposition.

Interstitial Granulomatous Dermatitis with Granuloma Annulare-Like Pattern Following Liposuction

Indu Agarwal¹, Antoinette Thomas¹, Mohit Agarwal², Thomas Cibull¹

¹Department of Pathology, NorthShore University Health System, Evanston, IL; ²Department of Radiology, Medical College of Wisconsin, Wauwatosa, WI, USA

Correspondence: Indu Agarwal
 Department of Pathology, NorthShore University Health System, 2650 Ridge Avenue, Evanston, Illinois, USA 60201
 Tel: +1-8475702779, Fax: +1-8475700289
 E-mail: induinpath@yahoo.co.in

No potential conflict of interest relevant to this article was reported.