

IMAGES

Solitary Labial Metastasis of Adrenocortical Carcinoma Resembling a Cystic Tumor in a Child

Hyunsuk Song¹, Dae Hee Han¹, Jang-Hee Kim²,
Myong Chul Park¹

Departments of ¹Plastic and Reconstructive Surgery and
²Pathology, Ajou University Hospital, Ajou University School of
Medicine, Suwon, Korea

Correspondence: Myong Chul Park
Department of Plastic and Reconstructive Surgery, Ajou University Hospital,
Ajou University School of Medicine, World cup-ro 164, Yeongtong-gu,
Suwon443-721, Korea
Tel: +82-31-219-5614, Fax: +82-31-219-5610, E-mail: mpark@ajou.ac.kr

No potential conflict of interest relevant to this article was reported.

Received: 26 Apr 2013 • Revised: 25 Jun 2013 • Accepted: 26 Jun 2013
pISSN: 2234-6163 • eISSN: 2234-6171
<http://dx.doi.org/10.5999/aps.2013.40.5.645> • Arch Plast Surg 2013;40:645-647

Copyright © 2013 The Korean Society of Plastic and Reconstructive Surgeons
This is an Open Access article distributed under the terms of the Creative Commons
Attribution Non-Commercial License (<http://creativecommons.org/licenses/by-nc/3.0/>)
which permits unrestricted non-commercial use, distribution, and reproduction in any
medium, provided the original work is properly cited.

Facial skin metastases account for less than 0.5% of patients with metastatic cancer and most of them originate from malignant melanoma [1]. Because the clinical presentations of skin metastasis are often non-specific, early detection is very difficult. Adrenocor-

tical carcinoma (ACC) is a rare tumor accounting for 0.2% of all childhood cancers and has an incidence of 1-2 cases per 1.7 million persons [2]. Until now, cutaneous metastases have rarely been reported. Herein, we report on a 4-year-old girl who presented with an elevated mass resembling a cystic tumor on her right upper lip that was diagnosed as metastatic ACC.

A 4-year-old girl who was diagnosed with Turner syndrome recently visited our hospital for the evaluation of a right maxillary area subcutaneous mass. The mass was 3.5 cm × 2.5 cm in size and had developed 6 months earlier. It was round, non-tender and fixed and, clinically, seemed to be a cystic tumor.

The patient had a history of adrenalectomy due to left ACC 2 years earlier. At that time the tumor had been 7.5 cm × 6.5 cm × 4.5 cm in size and weighed 102 g (Fig. 1). The resection margins were tumor-free, and there was no lymph node enlargement or local invasion. According to the modified staging system of pediatric ACC, it was stage I. After complete resection of the ACC, no further symptoms or signs had developed until 18 months later, when she felt a palpable mass on her right maxillary area.

The preoperative computed tomography (CT) and ultrasonography of the maxillary mass indicated the possibility of a solid tumor (Fig. 2). The mass was deep in the subcutaneous level, so the approach was performed through the right upper oral mucosa. After penetrating the orbicularis oris muscle, a well-encap-

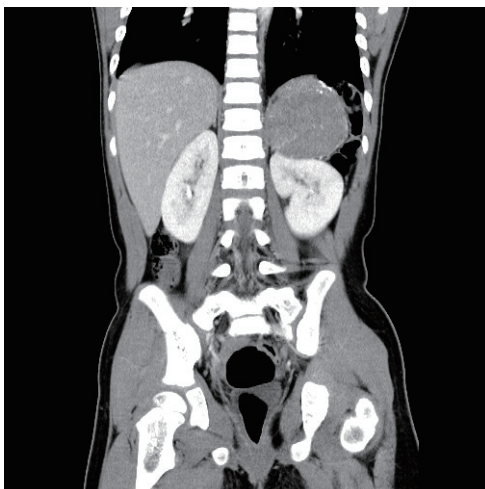

Fig. 1.

The patient had a history of adrenal cortical carcinoma 2 years before the metastatic presentation. There was a huge mass (7 cm × 6 cm × 4 cm) on the adrenal gland consistent with adrenocortical carcinoma.

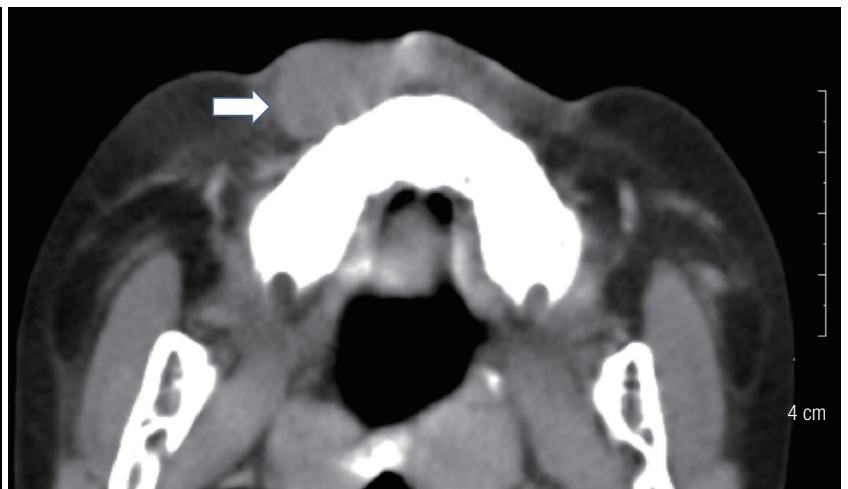

Fig. 2.

Preoperative computed tomography findings. Facial computed tomography findings showing a solid mass (white arrow) with irregular margins in the right premaxillary area.

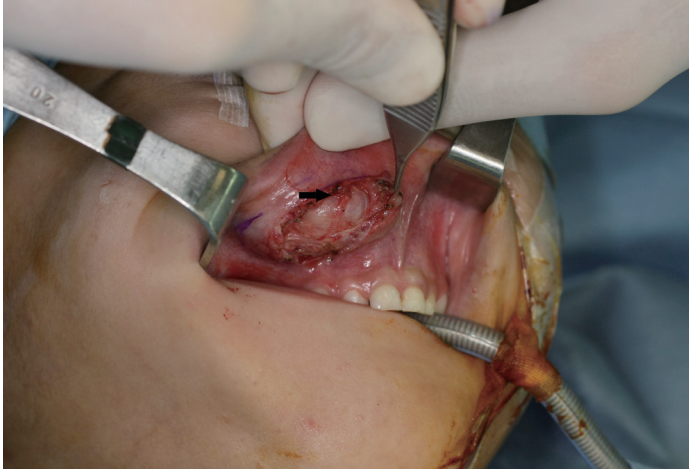


Fig. 3. Intraoperative view. The well-encapsulated round mass (black arrow) was noted while the orbicularis oris muscle was being held with Adson tissue forceps.

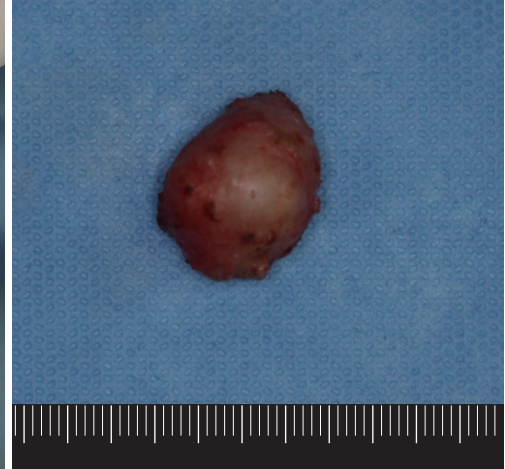

Fig. 4. Postoperative gross mass view. A 2.2 cm × 1.5 cm × 1.5 cm specimen was removed.

sulated mass was found (Fig. 3). The mass was overlying the subcutaneous and muscle layer. The mass was excised entirely, preserving normal adjacent tissue without any rupture. The specimen was 2.2 cm × 1.5 cm × 1.5 cm in size and sent to the pathology department (Fig. 4).

Histological evaluation of the mass showed a high nuclear grade, atypical mitosis, sinusoidal invasion, and a mitotic rate of 40/50 in the high power field (Fig. 5). This histopathology was consistent with that of the ACC excised 2 years earlier. The laboratory studies of the hormone level revealed a normal range. Additionally, there was no evidence of lymph node enlargement or other organ metastasis in CT and positron emission tomography (PET)-CT evaluation. Therefore, she did not receive chemotherapy or radiation.

During 2 years of follow-up, there was no evidence of local recurrence and no distant metastasis in facial and abdominal CT or PET-CT evaluation.

ACC is a rare malignancy, and it is associated with p53 mutation in children. Generally, ACC can be classified as a functional or non-functional tumor. Children with ACC most commonly present with virilization. Although several studies have shown that patients with functional tumors have a slightly better outcome, other studies contradict this finding [3]. 75% of cases in children are localized to the adrenal gland (stage I and stage II); however, in adult patients, 30% to 85% of patients have distant metastasis at the time of presentation. The most common sites of metastasis are the liver, local lymph nodes, lung,

peritoneum, and bone [4]. However, cutaneous metastases have rarely been reported. In the previous report, the facial metastatic lesion existed concomitantly with ACC, but in our case the metastatic lesion occurred 18 months after the excision of the primary ACC. Therefore, our case is the first report of ACC with delayed metastasis to the facial area.

For primary ACC, histopathologic findings of tumor necrosis, a mitotic rate of more than 5 of 50 in the high power field, and atypical mitotic figures are associated with reduced disease-free survival [4]. In metastatic ACC, poor prognostic factors are liver metastases, bone metastases, more than 5 metastatic lesions, more than 2 tumoral organs, a high mitotic count of more than 20 of 50 in the high power field, and presence of atypical mitoses. In contrast, patients whose metastases were diagnosed more than 1 year after resection of the primary ACC had a better outcome than those who developed a recurrence before this date [5]. In our case, the poor prognostic factors were atypical mitosis and a high mitotic rate (40 of 50 in the high power field), which were found in both the original ACC 2 years earlier and the metastatic lesion. However, late recurrence of the metastasis (18 months after adrenalectomy) is a good prognostic factor.

In patients with advanced or metastatic tumors, resection of the metastatic disease is indicated if possible. Otherwise, they can be treated with adjuvant chemotherapy, mitotane, and radiation. There has been no analysis of the efficacy of adjuvant treatment in patients with advanced-stage disease [4]. If complete

resection is possible, no further therapy is indicated. Close observation with imaging and endocrine studies is needed.

Our case is noteworthy because delayed metastasis of ACC to the facial skin is extremely rare, and there was only a solitary metastatic lesion without any tumor recurrences or distant metastases.

The clinical presentations of skin metastasis are highly variable, so they may go unnoticed for a long time. Most skin metastasis appears as rapidly growing solitary or multiple round or subcutaneous nodules, and the lesion is usually painless [3]. In our case, the mass had round, non-tender, and fixed features. Because the mass seemed clinically to be a cystic tumor and no symptoms or signs had developed until 18 months after resection of the primary ACC, early detection of the skin metastasis was difficult. Additionally, there was no evidence of metastasis in the regular oncology work-up. Although the punch biopsy revealed capillary proliferation, we used imaging studies (CT and ultrasonography) with a high index of suspicion and performed a surgical excision for accurate diagnosis.

In conclusion, careful examination with various diagnostic methods and total excisional biopsy are recommended for early detection of metastasis if there is any suspicious skin lesion in patients with a history of malignancy.

References

1. Lookingbill DP, Spangler N, Helm KF. Cutaneous metastases in patients with metastatic carcinoma: a retrospective study of 4020 patients. *J Am Acad Dermatol* 1993;29:228-36.
2. Miller RW, Young JL Jr, Novakovic B. Childhood cancer. *Cancer* 1995;75:395-405.
3. Satter EK, Barnette DJ. Adrenocortical carcinoma with delayed cutaneous metastasis. *J Cutan Pathol* 2008;35:677-80.
4. Stojadinovic A, Ghossein RA, Hoos A, et al. Adrenocortical carcinoma: clinical, morphologic, and molecular characterization. *J Clin Oncol* 2002;20:941-50.
5. Assie G, Antoni G, Tissier F, et al. Prognostic parameters of metastatic adrenocortical carcinoma. *J Clin Endocrinol Metab* 2007;92:148-54.

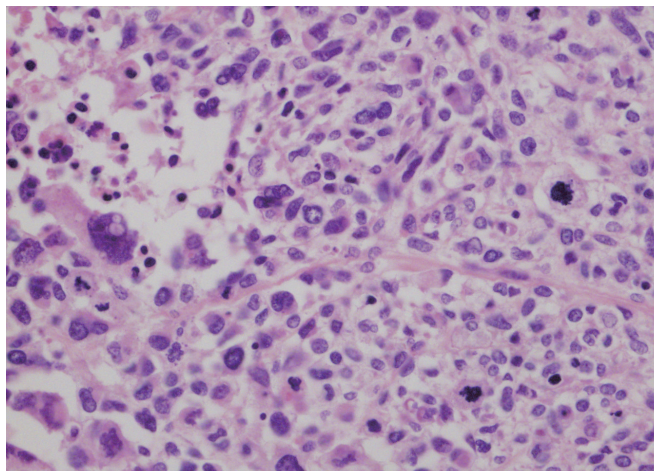


Fig. 5.

Pathologic findings. The high power view of the metastatic adrenocortical carcinoma shows pleomorphic tumor cells, increased mitoses, and necrosis similar to that of the previous adrenocortical carcinoma (H&E, $\times 400$).

Breast Reconstruction in a Previously Explanted Patient: An Interesting Anatomical Anomaly

Francesco Maria Egro, Grant Walter Carlson

Emory Division of Plastic and Reconstructive Surgery, Atlanta, GA 30308, USA

Correspondence: Francesco Maria Egro
Emory Division of Plastic and Reconstructive Surgery, Atlanta, GA 30308, USA
Tel: +1-7708264642, E-mail: francescoegro@gmail.com

No potential conflict of interest relevant to this article was reported.

Received: 14 May 2013 • Revised: 12 Jun 2013 • Accepted: 9 Aug 2013
pISSN: 2234-6163 • eISSN: 2234-6171
<http://dx.doi.org/10.5999/aps.2013.40.5.647> • Arch Plast Surg 2013;40:647-649

Copyright © 2013 The Korean Society of Plastic and Reconstructive Surgeons
This is an Open Access article distributed under the terms of the Creative Commons Attribution Non-Commercial License (<http://creativecommons.org/licenses/by-nc/3.0/>) which permits unrestricted non-commercial use, distribution, and reproduction in any medium, provided the original work is properly cited.

Breast prostheses have been available since the 1950s, serving the purpose of improving the breast contour in breast reconstruction and augmentation. Explanation of breast implants may be required for a variety of reasons including capsular contracture, damage or change in size and shape of the implant, or fear of the potential adverse effects of the implants on health [1]. The complications and effects of explantation are