

Posttraumatic Ectopic Nail

So-Min Hwang, Ka-Hyung Cho, Hyung-Do Kim,
Yong-Hui Jung, Hong-Il Kim

Aesthetic, Plastic and Reconstructive Surgery Center, Good Moonhwa Hospital, Busan, Korea

Correspondence: So-Min Hwang
Aesthetic, Plastic and Reconstructive Surgery Center, Good Moonhwa Hospital,
119 Beomil-ro, Dong-gu, Busan 601-803, Korea
Tel: +82-51-630-0199, Fax: +82-51-630-0145, E-mail: mdoc98@hanmail.net

This study was presented at the 2nd Research and Reconstructive Forum on June 1-2, 2012, in Gwangju, Korea.

No potential conflict of interest relevant to this article was reported.

Received: 8 Jun 2013 • Revised: 1 Jul 2013 • Accepted: 2 Jul 2013
pISSN: 2234-6163 • eISSN: 2234-6171
<http://dx.doi.org/10.5999/aps.2013.40.6.793> • Arch Plast Surg 2013;40:793-794

Copyright © 2013 The Korean Society of Plastic and Reconstructive Surgeons
This is an Open Access article distributed under the terms of the Creative Commons Attribution Non-Commercial License (<http://creativecommons.org/licenses/by-nc/3.0/>) which permits unrestricted non-commercial use, distribution, and reproduction in any medium, provided the original work is properly cited.

Ectopic nail is a very rare disease entity where the nail grows in other places than the nail bed due to the abnormal location or direction of the nail matrix. Since it was first reported in 1931, approximately 50 cases have been described in the literature. It is generally classified into two types: congenital ectopic nail due to genetic aberrations and the acquired one, also known as posttraumatic ectopic nail. The former accounts for most cases [1-3].

An 8-year-old girl visited us with a chief complaint of nail deformity in the left thumb (Fig. 1A). At the age of 2 years, the patient sustained a soft tissue crushing injury because of the entrapment of the distal phalanx of the left thumb in a chink in the door. Three months after spontaneous wound healing, the patient developed a swelling of the nail root accompanied by a hard eschar. Afterwards, the patient presented with a nail-like keratotic lesion. It had grown persistently up to the time of presentation at our clinic with a similar rate of growth as the normal nail. However, the patient presented with no other symptoms such as pain or tenderness. The patient had normal radiological findings (Fig. 1B). On physical examination, the patient had an additional nail-like keratotic lesion 7 mm × 5 mm in size, growing in the eponychium, whose location was remote from the normal nail. The clinical impression was posttraumatic ectopic nail. Under intravenous anesthesia, we made a 1-cm longitudinal incision from the radial edge of the lunula to the proximal side, taking care not to damage the matrix of the normal nail. We found a fully developed the ectopic

nail unit separate from the normal one. There was no adhesion between the ectopic and normal nail units. Thus, using a No. 15 blade, we successfully removed the ectopic nail plate including its matrix en bloc (Fig. 2A, B). On histopathology, the nail bed was slightly stained with the hematoxylin-eosin (H&E) dye. In addition, there was an underlying presence of the nail matrix without a granular layer. Based on these findings, the patient was diagnosed with posttraumatic ectopic nail (Fig. 2C). At the most recent follow-up (6 months), it was determined that the patient had undergone an uneventful course without recurrent episodes or complications.

Ectopic nail, also termed onychoheterotopia, is a pathologic condition characterized by the persistent growth of the ectopic nail plate due to the presence of the ectopic nail matrix in other regions than the normal nail bed.

Little is known about the exact pathogenesis of ectopic nail, for which various hypotheses have been proposed. According to Ohya et al., an ectopic nail is a teratoma that is formed by stray germ cells (cited in Jeong et al. [2]). According to Kikuchi et al. [4], the pathogenesis of ectopic nail is closely associated with rudimentary nail or hidden polydactyly. According to some reports, it is associated with congenital palmar nail syndrome, Pierre Robin syndrome, or the aberration of the long-arm of chromosome 6. This provides a possibility that its pathogenesis might have a familial tendency or genetic inheritance. On the other hand, posttraumatic ectopic nail may occur as a result of acute single overwhelming injury or chronic repeated minor injury. That is, posttraumatic ectopic

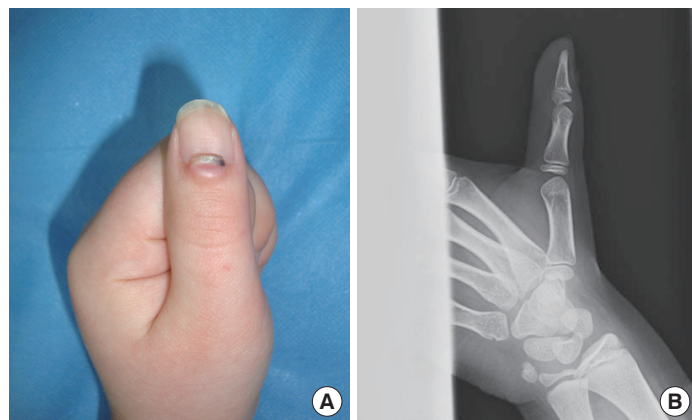


Fig. 1. Preoperative findings of the case. (A) A solitary, localized, well-demarcated, 7 mm × 5 mm, whitish hyperkeratotic nail-like skin lesion on the center of the left thumb. (B) No underlying bone deformity is visible on plain radiography.

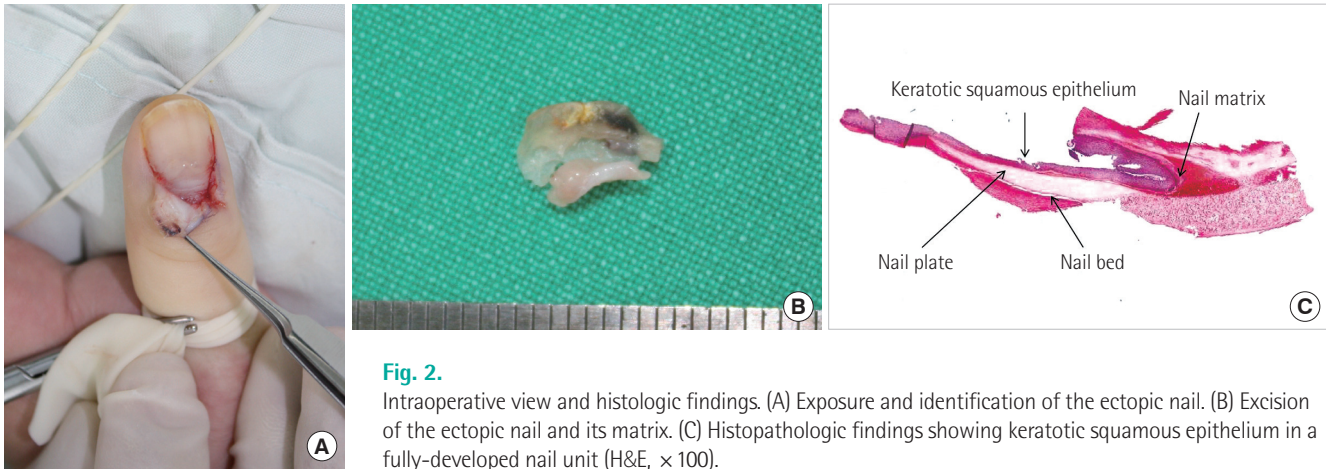


Fig. 2.

Intraoperative view and histologic findings. (A) Exposure and identification of the ectopic nail. (B) Excision of the ectopic nail and its matrix. (C) Histopathologic findings showing keratotic squamous epithelium in a fully-developed nail unit (H&E, $\times 100$).

nail occurs when the germinal matrix of the nail is split and its split section is implanted in the skin [1-4].

Clinical characteristics of ectopic nail include the small outgrowth of a deviant nail or complete double fingernail malformation. In congenital cases, an ectopic nail typically grows alongside the normal nail. Due to the abnormal location of the nail matrix, however, it may also be deviated from the normal nail. Congenital ectopic nail most commonly affects the palmar aspect of the fifth finger, followed by the palmar surface of the fourth finger, the first and third finger, and the second digit in decreasing order. On the other hand, posttraumatic ectopic nail affects the dorsal aspect of the finger the most commonly. However, few case reports have shown that it occurs in the toe or other body regions than the finger or toe [1-4].

Most cases of ectopic nail are asymptomatic, but their clinical findings may include pain, pruritis, and swelling. It may also invade the normal nail matrix, thus disturbing the growth of the normal nail and causing a nail deformity. In addition, due to its contact with the underlying bone, it may also disturb the intramembranous ossification, thus leading to bone deformity [1-4].

Lew et al. [5] reported that ectopic nail is radiologically characterized by such findings as hypoplasia, thinning, or depression of the phalanx. It has also been reported that these radiological findings gradually disappear over time after surgical excision without causing serious problems. Radiological findings with an ectopic nail may vary depending on the depth and location of its matrix [2,5].

A diagnosis of ectopic nail is routinely made based on its typical clinical and histopathologic findings. Its histopathological findings are similar to those of the normal nail. That is, an ectopic nail is histopathologically

characterized by the presence of keratotic squamous epithelium, a corneous plate, and a matrix in a fully-developed nail unit. The ectopic nail is devoid of a nail bed but it also has a nail matrix [1-4].

The differential diagnosis should include foreign body reactions, rudimentary polydactyly, teratoma, hamartoma, split nail deformity, cutaneous horn, polyonychia associated with syndactyly, epidermolysis bullosa, and congenital ectodermal dysplasia [1-4].

The standard treatment regimen for ectopic nail is surgical excision. To prevent recurrence, the matrix of an ectopic nail should be removed. According to a review of the literature, however, there are few cases of recurrence after surgical excision [1-4].

Because ectopic nail is an extremely rare condition, it is likely to be overlooked during diagnosis. Based on its typical clinical and histopathologic findings, however, it may be easily diagnosed. Moreover, it may also be easily corrected with surgical excision. It is therefore mandatory to accurately understand the clinical characteristics of ectopic nail.

References

1. Riaz F, Rashid RM, Khachemoune A. Onychoheterotopia: pathogenesis, presentation, and management of ectopic nail. *J Am Acad Dermatol* 2011;64:161-6.
2. Jeong SY, Kim JH, Seo SH, et al. A case of congenital ectopic toenail. *Korean J Dermatol* 2008;46:106-8.
3. Kim BY, Yeon JH, Min SU, et al. A case of posttraumatic ectopic nail. *Korean J Dermatol* 2009;47:491-3.
4. Kikuchi I, Ono T, Ogata K. Ectopic nail: case reports. *Plast Reconstr Surg* 1978;61:781-3.
5. Lew BL, Park JH, Kim NI. Congenital ectopic toenail: a case report and review of the literature. *Ann Dermatol* 2004;16:109-12.