

(5) Recipient vein: With respect to the choice of recipient vein(s), we recommend the use of the deep venous system, which is unlikely to be affected during secondary debulking procedures.

The senior author has used the techniques described above, over a 25-year period (1990–2015), with good results and without any problems at the donor site. On the basis of our experience and the findings of the currently available anatomical studies, surgeons can expect to achieve low complication rates and improved outcomes with the use of the groin lymph node free flap.

## References

1. Cheng MH, Chen SC, Henry SL, et al. Vascularized groin lymph node flap transfer for postmastectomy upper limb lymphedema: flap anatomy, recipient sites, and outcomes. *Plast Reconstr Surg* 2013;131:1286-98.
2. Lopez-Monjardin H, de la Pena-Salcedo JA. Techniques for management of size discrepancies in microvascular anastomosis. *Microsurgery* 2000;20:162-6.
3. Zhang H, Chen W, Mu L, et al. The distribution of lymph nodes and their nutrient vessels in the groin region: an anatomic study for design of the lymph node flap. *Microsurgery* 2014;34:558-61.
4. Dayan JH, Dayan E, Kagen A, et al. The use of magnetic resonance angiography in vascularized groin lymph node transfer: an anatomic study. *J Reconstr Microsurg* 2014;30:41-5.
5. Scaglioni MF, Suami H. Lymphatic anatomy of the inguinal region in aid of vascularized lymph node flap harvesting. *J Plast Reconstr Aesthet Surg* 2015;68:419-27.

## Breakthrough Technique for Free Tissue Transfer of Poorly Vascularized Lower Extremity: Arteriovenous Loop Revisited

Hee-Eun Cho, Si-Gyun Roh, Nae-Ho Lee, Kyung-Moo Yang

Department of Plastic and Reconstructive Surgery, Chonbuk National University Hospital, Jeonju, Korea

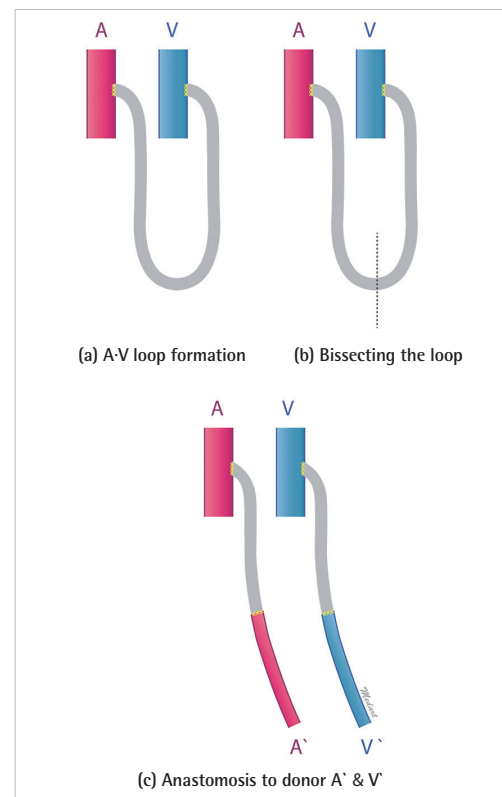
**Correspondence:** Si-Gyun Roh  
Department of Plastic and Reconstructive Surgery, Chonbuk National University Hospital, Chonbuk National University Medical School, 20 Geonjiro Deokjin-gu, Jeonju 54907, Korea  
Tel: +82-63-250-1860, Fax: +82-63-250-1866, E-mail: pssroh@jbnu.ac.kr

No potential conflict of interest relevant to this article was reported.

Received: 28 Feb 2015 • Revised: 30 Mar 2015 • Accepted: 30 Mar 2015  
pISSN: 2234-6163 • eISSN: 2234-6171  
<http://dx.doi.org/10.5999/aps.2015.42.5.652> • Arch Plast Surg 2015;42:652-655

Copyright © 2015 The Korean Society of Plastic and Reconstructive Surgeons  
This is an Open Access article distributed under the terms of the Creative Commons Attribution Non-Commercial License (<http://creativecommons.org/licenses/by-nc/3.0/>) which permits unrestricted non-commercial use, distribution, and reproduction in any medium, provided the original work is properly cited.

Severely damaged lower extremities with poor vessels are challenging situations for reconstructive surgeons. Patients with such extremities may have problems resulting from an inadequacy of recipient vessels caused by factors such as arterial occlusive disease or



**Fig. 1.** Schematic representation of an arteriovenous loop (A-V loop).

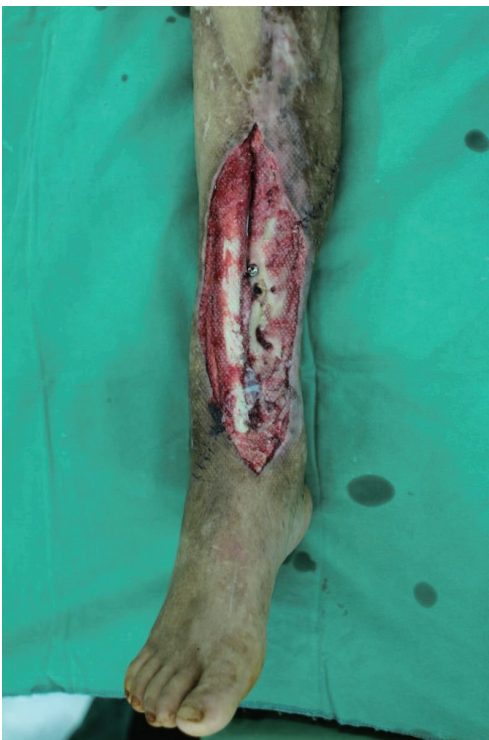previous accidents or surgery. In such cases, a vein graft is considered. It allows for anastomoses outside the injury zone or compensates for short pedicles, thereby reducing the risk of tension and the concomitant hazard of thrombosis [1]. However, vein grafts prolong the ischemia time of the flap, and adjusting the length of these grafts is difficult [2]. Further, we can consider an arteriovenous loop to anastomose a vessel when we need additional pedicle length or an adequate recipient vessel. In such a case, we first make a temporary arteriovenous loop between the artery and the vein. A few minutes later, we check for suitable vascular flow in the loop. Then, after bisecting this loop, we anastomose the new vessels to the donor vessels in an end-to-end manner (Fig. 1). This technique can be performed as a one- or two-stage procedure. The use of arteriovenous loops in a one- or two-stage procedure has been subject to debate, and as of now, there is no general agreement on its indications [2].

In this report, we discuss the case of a patient who underwent free flap surgery using an arteriovenous loop by an immediate one-stage procedure and suggest that this technique be considered a

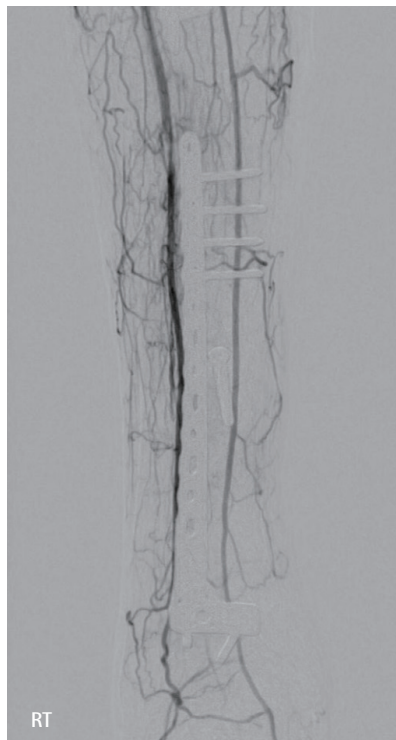breakthrough technique for a free flap transfer of poorly vascularized lower extremities.

A 58-year-old man was referred to the Department of Plastic Surgery for a soft-tissue defect of the right lower leg resulting from a motorcycle accident. He had no history of any underlying disease such as hypertension, diabetes, or peripheral arterial occlusive disease. However, unfortunately, he had a previous history of an anterolateral thigh perforator free flap because of chronic osteomyelitis with a soft-tissue defect on the same lower leg due to severe trauma caused by a motorcycle accident 5 years previously.

When he transferred, he had an open wound on an open fracture at one-third of the distal shaft of the tibia with exposure of the bone and hardware and continuous draining overlying his tibia fracture site (Fig. 2). *Pseudomonas* grew from the open pus culture overlying his wound. Antibiotic therapy failed, and the infected nonunion of his fracture was diagnosed. A number of debridement procedures were performed. After observing the little infection wound, we prepared for reconstruction with a latissimus dorsi myocutaneous free flap.



**Fig. 2.** A 58-year-old man injured in a motorcycle accident, preoperative: hardware was exposed along with his bone and soft tissue.



**Fig. 3.** Angiogram obtained prior to free flap reconstruction: diffuse atrophic change in the right lower extremity and no obvious stenosis of the right posterior tibial artery and proximal portion of the peroneal artery were observed. RT, right leg.

We obtained an angiogram of the right lower extremity for the preoperative assessment; it showed a diffuse atrophic change in the right lower extremity but no obvious stenosis of the right posterior tibial artery and proximal portion of the peroneal artery. The collateral circulation of the distal part of the right posterior tibial artery and peroneal artery is shown in Fig. 3.

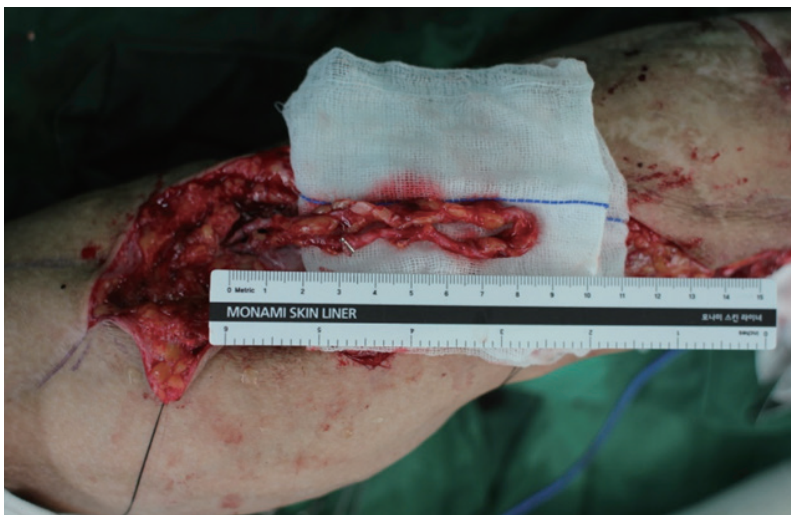However, in the operative field, there were also no available healthy and well-vascularized recipient vessels due to the patient's previous injury. There were no adequate recipient vessels below the patient's

popliteal vessels for anastomosis. Therefore, we designed a temporary arteriovenous loop by using the left lesser saphenous vein between the popliteal artery and vein (Fig. 4).

Thus, we created new reliable recipient vessels by using this arteriovenous loop at one stage. After obtaining adequate vascular flow, the loop was bisected and the vascular flow was re-established successfully. The donor tissue (latissimus dorsi myocutaneous flap) was subsequently transferred. We anastomosed the divided vessels in an end-to-end manner to the distal thoracodorsal artery and vein, which were used for the donor pedicle of the free flap. After the operation, there were no postoperative complications (Fig. 5). Follow-up at 12 months showed no evidence of osteomyelitis or flap failure.

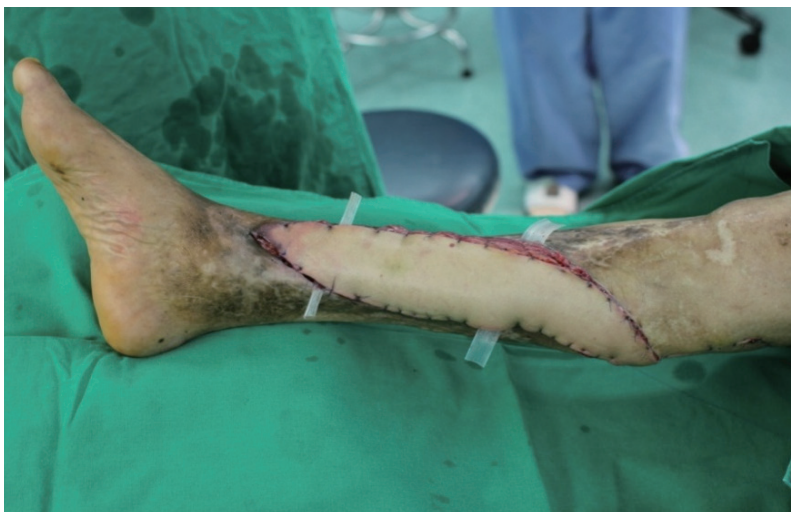Using a one-stage arteriovenous loop enabled not only satisfactory patent anastomosis but also vessel diameter extension, particularly in ischemic limbs. An arteriovenous loop permits the identification of the initial vascular adequacy of the recipient vessel. We can rapidly detect leakage from branches if there are problems with the graft. In addition, vessel distension *via* arteriovenous flow pulsation prevents errors related to the vessel length because of vessel spasms. It permits distension at normotensive pressures, avoiding the endothelial injury that occurs at much higher pressures than usual in manual distension [3]. Technically, it provides an opportunity for the repair of leakage and the removal of kinks in the vessels before the free tissue transfer. This technique can be performed easily, and monitoring the patency does not require a long period of time. Following loop bisection, end-to-end anastomosis to the donor pedicle is possible outside of the injured zone. It also enables immediate vascularization of the flow in the vein; thus, the ischemia time can be decreased. Further, it can decrease the ischemia time of the vein graft itself [4]. The simple vein graft is only performed when the donor and recipient vessels are all identical. However, the arteriovenous loop has the advantage of creating new vessels at the problematic recipient vessel site. The use of the lesser saphenous vein has some advantages because of its more-than-adequate length, approximately 40–50 cm, and its thin walls with a nearly constant diameter [4].

Lind et al. [5] have reported that the two-stage approach is more manageable. When the procedure is staged, the fistula can be observed for several days to be certain that it has adequate blood flow to support the free flap. Nevertheless, the one-stage



**Fig. 4.**

A-V loop created from a branch of the popliteal artery: the A-V loop was established using the patient's contralateral lesser saphenous vein system.



**Fig. 5.**

Postoperative appearance following latissimus dorsi myocutaneous free flap using the A-V loop: the wound healed, and there were no further complications.



procedure has logistic and economic advantages over the two-stage procedure [2]. However, some other surgeons advocate the use of the one-stage procedure. The largest case series on this topic was published in Taiwan, with 34 cases: 28 one-stage and six two-stage procedures. In this case series, the occlusion rate in the one-stage procedure group was 29%, with an 11% flap failure rate, whereas 50% of the two-stage loops occluded, with a 33% flap loss rate. The authors demonstrated that two-staged arteriovenous loop is even more disappointing from the point of flap survival [2].

In summary, the use of an arteriovenous loop makes a neovascular system possible and is a useful method for solving unexpected vascular problems at an inadequate recipient site. Therefore, we conclude that an arteriovenous loop can be used as a breakthrough tool to overcome unexpected problems of micro-reconstruction in poorly vascularized lower extremities.

## References

1. Hallock GG. The interposition arteriovenous loop revisited. *J Reconstr Microsurg* 1988;4:155-9.
2. Cavadas PC. Arteriovenous vascular loops in free flap reconstruction of the extremities. *Plast Reconstr Surg* 2008;121:514-20.
3. Freedman AM, Meland NB. Arteriovenous shunts in free vascularized tissue transfer for extremity reconstruction. *Ann Plast Surg* 1989;23:123-8.
4. Vlastou C, Earle AS. Short saphenous vein grafts as an aid to microsurgical reconstruction of the lower extremity. *J Reconstr Microsurg* 1988;4:145-54.
5. Lind B, McCarthy W, Derman G, et al. Arteriovenous loop grafts for free tissue transfer. *Vasc Endovascular Surg* 2012;46:30-3.

## Segmental Hemihyperplasia-Related Macroductyly with Congenital Renal Agenesis: A Hand Surgeon's Point of View

João Nunes da Costa, Júlio Matias

*Department of Plastic, Reconstructive and Maxillofacial Surgery, Hospital de Egas Moniz, Lisbon, Portugal*

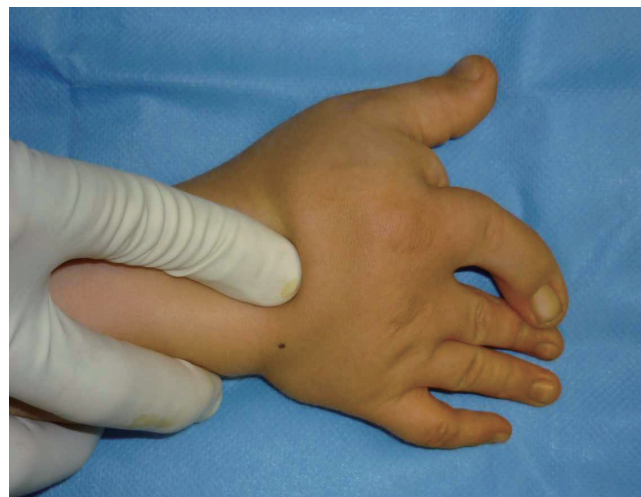**Correspondence:** João Nunes da Costa  
Department of Plastic, Reconstructive and Maxillofacial Surgery, Hospital de Egas Moniz, Rua Diogo de Silves, 35, 5.º Esq - 1400-107 Lisbon, Portugal  
Tel: +35-1919828668, Fax: +35-1210432050, E-mail: jlnco@icm.gov.pt

No potential conflict of interest relevant to this article was reported.

Received: 17 Feb 2015 • Revised: 13 May 2015 • Accepted: 1 Jun 2015  
pISSN: 2234-6163 • eISSN: 2234-6171  
<http://dx.doi.org/10.5999/aps.2015.42.5.655> • Arch Plast Surg 2015;42:655-658

Copyright © 2015 The Korean Society of Plastic and Reconstructive Surgeons  
This is an Open Access article distributed under the terms of the Creative Commons Attribution Non-Commercial License (<http://creativecommons.org/licenses/by-nc/3.0/>) which permits unrestricted non-commercial use, distribution, and reproduction in any medium, provided the original work is properly cited.

Hemihyperplasia is a clinical condition defined as an asymmetric enlargement of one side of the body, usually in the upper and lower extremities, head, trunk, and internal organs. It may affect the entire hemibody or be segmental, and can present in a unilateral or crossed manner. Hemihyperplasia has a calculated incidence of 1:86,000 newborns [1] and is usually sporadic, but some familial occurrences have been described. It can be associated with a syndrome or be isolated, the latter usually being a diagnosis of exclusion. When affecting the hand, hemihyperplasia



**Fig. 1.**

Patient at two years of age, showing right hand radial side macroductyly with index finger clinodactyly.