

developed a mass two weeks after the extravasation of anticancer drugs, which is consistent with the clinical manifestation of calcinosis cutis arising from the extravasation of calcium chloride. According to Goldminz et al. [5], the pathophysiology of calcinosis cutis is based on tissue damage arising from the extravasation of a solution followed by the deposition of crystalline or insoluble calcium phosphate minerals.

However, we did not use intravenous calcium therapy. We assume that this case was solely caused by the extravasation of anticancer drugs. The tissue damage caused by the extravasation of anticancer drugs may be assumed to have played an important role in the onset of calcinosis cutis. This is the first case report of calcinosis cutis caused by the extravasation of intravenous anticancer drugs. We believe that our rare case may help elucidate the pathogenesis of calcinosis cutis.

References

- Walsh JS, Fairley JA. Calcifying disorders of the skin. *J Am Acad Dermatol* 1995;33:693-706.
- Reiter N, El-Shabrawi L, Leinweber B, et al. Calcinosis cutis: part I. Diagnostic pathway. *J Am Acad Dermatol* 2011;65:1-12.
- Lestringant GG, Masouye I, El-Hayek M, et al. Diffuse calcinosis cutis in a patient with congenital leukemia and leukemia cutis. *Dermatology* 2000;200:147-50.
- Kagen MH, Bansal MG, Grossman M. Calcinosis cutis following the administration of intravenous calcium therapy. *Cutis* 2000;65:193-4.
- Goldminz D, Barnhill R, McGuire J, et al. Calcinosis cutis following extravasation of calcium chloride. *Arch Dermatol* 1988;124:922-5.

A Rare Case of an Epidermal Inclusion Cyst in the Joint Capsule of the Thumb

So-Min Hwang¹, Sang-Hwan Lee¹, Min-Wook Kim¹, Hwal-Woong Kim²

¹Aesthetic, Plastic, and Reconstructive Surgery Center, Busan; ²Department of Pathology, Good Moonhwa Hospital, Busan, Korea

Correspondence: Sang-Hwan Lee

Aesthetic, Plastic and Reconstructive Surgery Center, Good Moonhwa Hospital, 119 Beomil-ro, Dong-gu, Busan 48735, Korea
Tel: +82-51-630-0199, Fax: +82-51-630-0145
E-mail: Sangwind@hanmail.net

This article was presented as a poster at the 72nd Congress of the Korean Society of Plastic and Reconstructive Surgeons on November 7-9, 2014 in Seoul, Korea.

No potential conflict of interest relevant to this article was reported.

Received: 13 Apr 2015 • Revised: 11 May 2015 • Accepted: 21 May 2015

ISSN: 2234-6163 • eISSN: 2234-6171
<http://dx.doi.org/10.5999/aps.2016.43.2.216>
Arch Plast Surg 2016;43:216-218

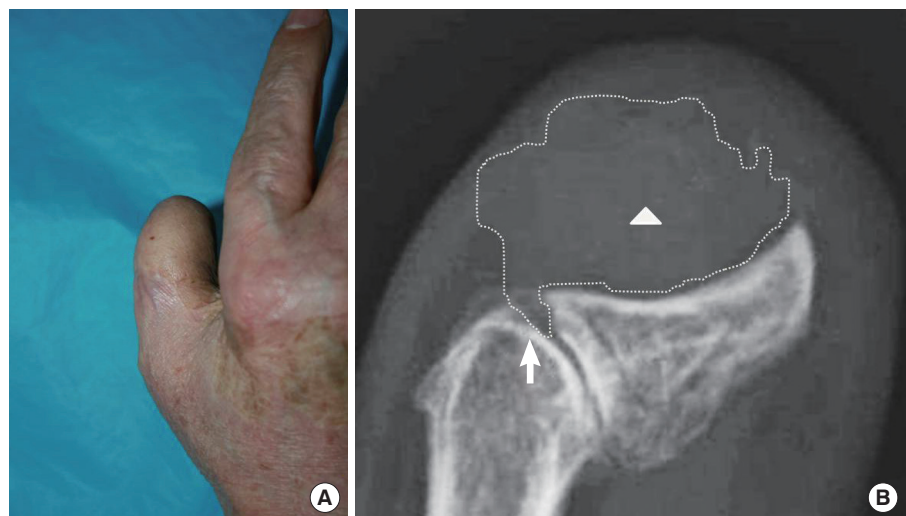


Copyright © 2016 The Korean Society of Plastic and Reconstructive Surgeons
This is an Open Access article distributed under the terms of the Creative Commons Attribution Non-Commercial License (<http://creativecommons.org/licenses/by-nc/4.0/>) which permits unrestricted non-commercial use, distribution, and reproduction in any medium, provided the original work is properly cited.

Epidermal inclusion cysts are one of the most common types of benign lesions that present in the subcutaneous tissue, and they are observed as fluctuating nodules [1]. They may occur in all body areas composed of squamous epithelium. However, intra-articular involvement of such cysts has been described very rarely in the literature [2]. We experienced a case of an epidermal inclusion cyst occurring in the joint capsule of the thumb in a patient with a past history of thumb trauma. Herein, we report our case and provide a review of the

Fig. 1.

(A) A 75-year-old male who had a mass within the interphalangeal joint capsule of the right thumb. (B) Widening of the interphalangeal joint space (white arrow) was observed and the origin of the radiolucent mass (white arrowhead) appeared to be located within the joint (dotted line, the boundary of the mass).



relevant literature.

A 75-year-old man visited us with a chief complaint of a six-month history of a mass in the interphalangeal joint of the right thumb. The patient complained of aggravated pain associated with the recently increased size of the mass (Fig. 1A). On physical examination, the patient exhibited tenderness. The patient also had fixed lesions with a firm consistency. Twenty-three years previously, the patient experienced a crushing injury to the left thumb, for which he underwent inguinal flap surgery and bone graft. However, the patient developed osteomyelitis in the bone graft site and underwent excision of the grafted bone tissue. Subsequently, the patient experienced multiple recurrences of epidermal inclusion cysts on the right thumb, which were excised. On plain radiography, the patient demonstrated radiolucent lesions accompanied by soft tissue swelling in the distal phalanx of the thumb. A connection was observed between the origin of the mass and the interphalangeal joint, based on which the mass was suspected to have occurred in the joint (Fig. 1B). In order to perform a differential diagnosis leading to the accurate diagnosis of the mass, we planned to excise and biopsy the mass under local anesthesia. By making an incision right superior to the lesion and dissecting the lesion, we were able to confirm the presence of a mass originating from the interphalangeal joint space (Fig. 2A). The mass was encapsulated and had a well-defined margin, and protruded to the epidermis in the right inferior region. It was easily dissected and then completely excised. Both the distal and proximal phalangeal joints were fixed using an arthrodesis. The excised

mass was measured to be 2.0×1.5 cm. It contained keratin and lipid debris from sebaceous secretions. Moreover, histopathological examination found an abundant presence of keratin on the interior side of the cystic wall composed of stratified squamous epithelium. However, no signs of other skin appendages were observed. Based on these findings, the patient was diagnosed with an epidermal inclusion cyst (Fig. 2B). During a six-month postoperative follow-up period, the mass did not recur and no other notable findings were observed (Fig. 3).

It is generally known that epidermal inclusion cysts occur in the dermis or subcutaneous layer. Most cases of epidermal inclusion cysts are asymptomatic. Therefore, an epidermal inclusion cyst is recognized when it protrudes to the superior region to the skin. In cases of epidermal inclusion cysts occurring in fingers, the differential diagnosis must exclude benign lesions, such as warts, fibroma, osteochondroma, and glomus tumor, as well as other conditions, such as squamous cell carcinoma and malignant melanoma. However, epidermal inclusion cysts are not associated with any typical signs and symptoms. This poses a differential diagnostic challenge for surgeons. In the current case, the patient presented with a gradual increase in a mass present in the interphalangeal joint of the thumb. It was palpable as a hardened mass, and was accompanied by intermittent pain and tenderness. The patient had a mass originating from the joint, based on which the patient was suspected of having heterotrophic ossification or osteochondroma. However, osteochondroma is characterized by heterotrophic calcification on plain radiography [3], which was not found in the current case.

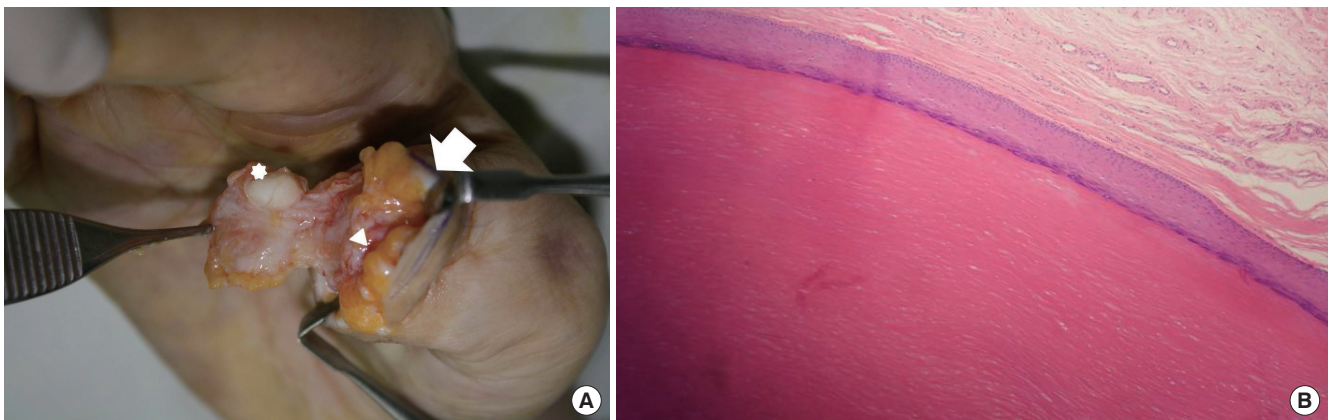


Fig. 2.

(A) The encapsulated mass (star-shaped, 2.0×1.5 cm) occurred within the interphalangeal joint (white arrowhead) of the right thumb (white arrow, distal head of proximal phalangeal bone). (B) In pathological findings, stratified squamous epithelial layers with laminated keratin layers were seen, and no hair follicles or skin appendages were present (H&E, $\times 100$).

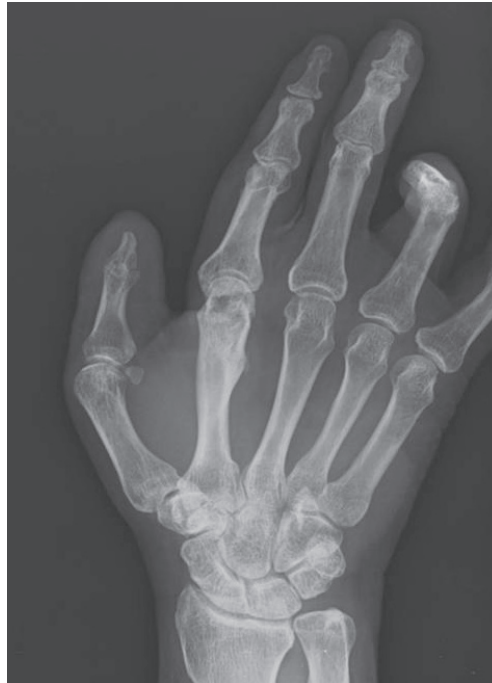

Fig. 3.
After six months, no evidence of recurrence was present in a simple postoperative radiograph.

According to a review of the literature, it is very rare for epidermal inclusion cysts to occur in the joint. Strauchen and Strefling [4] reported a case of an epidermal inclusion cyst occurring after arthroscopic surgery in the knee joint. However, this case occurred in the knee joint. To the best of our knowledge, no cases of epidermal inclusion cysts occurring in the interphalangeal joint have been described.

In the current case, the patient had a past history of trauma and developed the epidermal inclusion cyst at the site of the trauma. It can therefore be inferred that it is very unlikely for epidermal inclusion cysts to occur as congenital lesions. Based on other cases of epidermal inclusion cysts arising due to trauma, it is very likely that epidermal inclusion cysts in joints occur as a result of the squamous cells forming the epidermis being directly invaginated into the joint due to the trauma, or due to the invasion of a pre-existing epidermal inclusion cyst into the joint [5]. Still, little is known about the exact pathophysiology underlying the intra-articular presence of epidermal inclusion cysts, which deserves further study. In conclusion, our case highlights the possibility that epidermal inclusion cysts might also occur, albeit rarely, in the interphalangeal joints of the fingers. Recognizing this may be essential for avoiding unnecessary operations and amputations of fingers. Finally, we propose that masses found in the fingers should undergo histopathological examination in order to ensure that epidermal inclusion cysts are

properly diagnosed and appropriately treated.

References

1. Kim T, Oh SH, Lee JH. A case of subungual epidermal cyst. *Korean J Dermatol* 2010;48:506-9.
2. Noh JH, Roh YH, Lee HJ, et al. Intraarticular epidermal cyst of knee. *J Orthop Sci* 2013;18:340-2.
3. Nakajo M, Ohkubo K, Nandate T, et al. Intraosseous epidermal cyst of the distal phalanx of the thumb: radiographic and magnetic resonance imaging findings. *Radiat Med* 2005;23:128-32.
4. Strauchen JA, Strefling AM. Epidermal inclusion cyst of the meniscus: case report. *J Bone Joint Surg Am* 1982;64:290.
5. Ettinger RL, Manderson RD. Implantation keratinizing epidermoid cysts: a review and case history. *Oral Surg Oral Med Oral Pathol* 1973;36:225-30.

Pseudoangiomatous Stromal Hyperplasia Presenting as Rapidly Growing Bilateral Breast Enlargement Refractory to Surgical Excision

Jeong Woo Lee¹, Gyu Sik Jung¹, Jae Bong Kim¹, Kang Young Choi¹, Ho Yun Chung¹, Byung Chae Cho¹, Ji Young Park², Hye Jung Kim³, Ho Yong Park⁴, Jung Dug Yang¹

Departments of ¹Plastic and Reconstructive Surgery, ²Pathology, ³Radiology, and ⁴Surgery, Kyungpook National University School of Medicine, Daegu, Korea

Correspondence: Jung Dug Yang
Department of Plastic and Reconstructive Surgery, Kyungpook National University School of Medicine, 130 Dongdeok-ro, Jung-gu, Daegu 41944, Korea
Tel: +82-53-420-5685, Fax: +82-53-425-3879, E-mail: lambyang@knu.ac.kr

This article was presented at the Fourth Research and Reconstructive Forum of the Korean Society of Plastic and Reconstructive Surgeons on April 3-4, 2014 in Pusan, Korea.

No potential conflict of interest relevant to this article was reported.

Received: 13 May 2015 • Revised: 3 Jun 2015 • Accepted: 9 Jun 2015
pISSN: 2234-6163 • eISSN: 2234-6171
<http://dx.doi.org/10.5999/aps.2016.43.2.218>
Arch Plast Surg 2016;43:218-221



Copyright © 2016 The Korean Society of Plastic and Reconstructive Surgeons
This is an Open Access article distributed under the terms of the Creative Commons Attribution Non-Commercial License (<http://creativecommons.org/licenses/by-nc/4.0/>) which permits unrestricted non-commercial use, distribution, and reproduction in any medium, provided the original work is properly cited.

Pseudoangiomatous stromal hyperplasia (PASH) is a benign proliferative mesenchymal lesion of the breast.